RESULT OF CLINICAL AND ULTRASOUND NEONATAL SCREENING FOR DEVELOPMENTAL DYSPLASIA OF THE HIP (DDH) IN JEDDAH, SAUDI ARABIA WITH CORRELATION OF RISK FACTORS

by

Dr. Soad M. Jaber

Consultant Paediatrician,

Department of Paediatrics, King Abdulaziz University Hospital

Jeddah, Saudi Arabia

Correspondence to:

Dr. Soad Jaber
Department of Pediatrics
King Abdulaziz University Hospital
P.O. Box 80215, Jeddah 21589
Saudi Arabia

ABSTRACT :

Risk factors for developmental dysplasia of the hip (DDH) were evaluated within 24 hours after birth in 809 Saudi and non-Saudi neonates. The incidence was found to be 10.3% for ultrasound abnormality and only 3.5% for clinically unstable hips. The hip instability was diagnosed clinically by limited abduction or positive ortalani test, ultrasonographic examination of the joint using both Graf's method[1] and Harck's dynamic test[2].

Risk factors previously known to be associated with DDH were confirmed in the present study. According to their incidence, they include female gender, family history of hip dysplasia, orthopaedic anomalies, increase birthweight and breech presentation. We have detected a new risk factor which is the infant of a diabetic mother. Ultra sonographic screening was considered to be the most reliable method for early detection in newly born babies. Negatively screened cases were followed up to almost one year and showed 0% incidence of late detected hip dysplasia or dislocation. The results were discussed in view of the available literature.

Keywords : DDH (Developmental dysplasia of the hip), KAUH (King Abdulaziz University Hospital)

INTRODUCTION AND AIM OF STUDY :

Developmental dysplasia of the hip (DDH) was suggested to be the underlying cause of hip instability. Hip joint instability is a disabling abnormality unless discovered and treated in the early stages of life. In most areas of the world, clinical screening of newborn babies for hip abnormalities has been advocated[3]. The aim is to ensure early detection and normal development and function of the hip joint by the end of adolescent period [4]. Ultrasound screening was recommended for DDH diagnosis. Subsequent researches have raised doubt about its medical effectiveness. The method was later reviewed in detail[5]. A considerable number of recent works has been published since then but there is still controversy about the role and effectiveness of such screening.

The paucity of available literature in using this protocol in the Kingdom of Saudi Arabia has encouraged the initiation of the present research.

The aims were as follows :

1) Firstly, to find out the incidence of hip joint instability due to developmental dysplasia in newborn within the first 24 hours of life in King Abdulaziz University Hospital, Western Region, Jeddah.
2) Secondly, to study the effectiveness of ultrasound screening in early detection, and
3) Finally, to correlate prenatal data with clinical and ultrasound findings at birth in order to find out the most important possible risk factors for the hip instability in this area.

MATERIAL AND METHOD :

The present study was carried out in the Nursery department at KAUH, Jeddah, Kingdom of Saudi Arabia from November 1995 until October 1996. Prenatal data, mode of delivery, birth weight, mother's illnesses and positive family history of DDH were recorded together with demographic data which included weight, sex, and nationality. Clinical and ultrasound examination of newborn were accomplished in the nursery every Monday and Friday. The screening included both Saudi and non-Saudi neonates within 24 hours of delivery. Neonates delivered during the rest of the week or those referred to the nursery department for other medical reasons including those suffering from neuromuscular disorders, were not included in the present study. The average number of newborn babies delivered was 14 per day with a total of 809 screened throughout the study.

Clinical assessment for the hip joint click, positive Ortolani or limited abduction was used. Ultrasound of the hip joint in the coronal plane was carried out in a special positioning apparatus (picture 1) following Graf's technique 1984 [(1)] (Table 1). Dynamic testing was carried out only on unstable hips.

Further evaluation and management of positive screened cases was done in the orthopaedic department and referred back for ultrasound follow-up. Risk factors were studied in relation to both clinical and ultrasound examination. Data collected included sex, nationality, side of pathology (right, left), family history, fetal presentation, gestational age, mode of delivery and weight at birth. The presence of orthopaedic congenital anomaly and chromosomal anomaly as Down's syndrome were noted.

RESULTS :

The incidence of positive clinical findings of the hip instability in neonates was 3.58%. They included all unstable hips and those with limited abduction. On the other hand, the incidence of abnormal ultrasound findings (including Graf's type IIa – hips) amounted to 10.3%.

Significant differences between both sexes were met with in the present study. The incidence of abnormality (+ve Ortolani or limited abduction) was 5.7% within the female newborn, compared to 1.5% within the male newborn. The difference between both sexes was statistically highly significant ($P<0.001$). The same highly significant differences were also found in ultrasound screening, 13.5% in female and 7.3% in males. Ultrasound screening showed slight differences in Saudi and non-Saudi newborn. The incidence of abnormality was slightly higher in Saudi babies (10.9%) compared to 9.7% in non-Saudi, whereas, the incidence of abnormal clinical findings was 4.2% in the former and 2.9% in the latter. Mean birth weight had no statistically significant impact for the clinical examination ($P=0.96$). It was 3.1335 kg in clinically stable hips and 3.1363 kg in unstable hips. On the other hand the mean birth weight (3.322 kg in the newborn) was higher with abnormal ultrasound examination than those newborn with normal ultrasound findings (3.1261kg). The difference was statistically significant ($P<0.001$).

The present study showed higher incidence of clinical abnormalities on the left side, 33 hips 56.9% of all abnormal hips, compared to the 25 right hips of which 43.1% were positive (Figure 1). Ultrasound screening also showed abnormal findings to be more on the left side, 98 hips, 47.2%, while 72 hips, 42.8%, belonged to the right side (Table 2).

The mode of delivery had an impact both on the clinical and ultrasound examinations. The incidence of clinical hip abnormality with vaginal delivery was 4.6% compared to only 0.6% in the cesarean section group. This is statistically highly significant ($P<0.001$). Ultrasound examination showed 6.8% hip ultrasound abnormality in the vaginal ones and 13.2% in the cesarean section.

Family history for DDH was observed in one female newborn who had 2 sisters diagnosed as DDH; the first sister at the age one year with asymmetry of gluteal folds who needed surgical correction and the other sister was diagnosed at 6 months of age with limited abduction. The baby girl in this study had normal clinical examination but ultrasound showed bilateral hip pathology (right IIa^- and left D hip).

Table 3 showed the relationship between prenatal data and the incidence of the hip joint instability. It showed the effect of fetal presentation, gestational age, mode of delivery, multiple pregnancy, orthopaedic congenital anomalies, mother's history of diabetes and finally, chromosomal anomalies such as Down's Syndrome.

DISCUSSION:

While the Ortalani[6] and Barlow's tests [7] remain of pivotal importance, the question that remains is whether clinical examination can be the only method for detecting all cases of hip instability due to DDH and whether these cases required immediate treatment. The deficiencies of clinical methods were outlined by many authors [8,9]. It was noted that the number of false negative cases on clinical screening are approximately the same as the number of true positive ones[10]. The ultrasound methodology for diagnosis of the present cases followed Graf's method for hip sonography[5].

Reliability of the method depends on measurement of the angles described by Graf's[11] with the standardized selected reference points and also using the dynamic evaluation for unstable hips[12,13]. Clinical assessment in the present study revealed that the over all incidence of abnormal clinical findings (positive clicks or limited abduction) reached 3.58%. The incidence of abnormal ultrasound, 10.3% for all hips, was significantly high. As expected, most of the clinically stable hips showed normal ultrasound screening, 1420 out of 1618 (87.76%), while those clinically unstable ones showed pathological ultrasound findings (1.85% of total) (Table 4). Analysis of the data showed that the total ultrasound and clinical findings correlated in 89.61% and were opposed in 10.39% of the cases (Figure 2). Neonates in whom abnormal clinical findings could not be confirmed by ultrasound (false positive clinical test) was 1.73%[14]. The important issue in the present study was that ultrasound can detect the hip pathology in clinically negative hips (false negative Ortolani) (8.65%)[15]. Depending only on clinical examination we might miss about 8.6% of hips that are in need of early management and which

might present as late hip dislocation. Clinically undetected cases included 2 hips (IIIa), 3 hips (IIc), 33 (D hip) and 102 (IIa^-) (Table 4). Risk factors predisposing to DDH were thoroughly discussed in literature[10,11,16,17,18]. The presence of merely one factor is more likely to increase the incidence of DDH in those infants compared to the general population. Well-known risk factors for DDH were also observed in the present study. Sex was a deciding factor for both clinical and ultrasound detected abnormalities[19]. The percentage of clinically unstable hips was 5.7% in females compared to 1.5% in males in the ratio of 4:1. Ultrasound positive cases were 13.5% among female and 7.3% in males in the ratio of 2:1 (Figure 3). Being a Saudi newborn or non-Saudi, is not a risk factor for ultrasound abnormalities, 10.9% Saudi 9.7% for non-Saudi, since the clinical examination showed abnormalities in 4.2% Saudi babies compared to 2.9% in non-Saudi (Figure 4). On the contrary, Bialik et al found the incidence of ultrasound abnormalities in black Ethiopian babies, 0.44%, while for white babies born in the same area it was 5.9% [20].

Regarding the side of the DDH for any of the subgroups, boys or girls, Saudi or non-Saudi, either for clinical or ultrasound findings, the left side was found to be more commonly affected (Figure 5).

In the presence of click (+ve Ortolani) ultrasound pathology was detected in 30 out of 58 hips, 51.7%. Those with both positive clinical and ultrasound findings were subdivided according to Graf's protocol i.e. $2IIa^+$, $12II^-$ 2(IIc) and 14(D) hip. As expected, this revealed that positive Ortalani or click test is a high risk factor[18,21,22], although it still shows low sensitivity in detecting pathological hip abnormalities[23] (Table 5).

The present study showed that newborn with pathological ultrasound findings had significantly higher birth weight (mean 3.22 kg) than those with normal sonographic findings (mean 3.126 kg) which is statistically significant $P<0.001$. These results were similar to those reported by Holen[15]. Premature or low birth weight or those with intrauterine growth retardation, weight inappropriate for gestational age, showed normal hip development both clinically and sonographically [19]. Although there was only one case with positive family history for two sisters diagnosed as late DDH, family history of DDH is still considered a risk factor of significant importance [11,15,16,24,25]. However, a positive family history was not considered a risk factor in the study of Ulvesczki et al[26] (Table 3).

The hip instability due to DDH was observed to be associated with other congenital orthopaedic anomalies e.g. club feet (Table 3). The same was reported as a risk factor by many authors[1,5,27]. Breech presentation at delivery, with all its different types, is a known risk factor for DDH. Forty-two abnormal hips were screened in the present study in association with 21 breech presentations. Nine of them (21.4%) showed abnormal ultrasound findings and only 2 (4.76%) were clinically unstable[4,11,18,19,21,24,25]. This was not considered as a risk factor by Ribon from Italy [23].

Two hundred twenty-one neonates were delivered by Cesarean Section (C.S.), 27.3% of all deliveries. This is a high percentage which is difficult to be interpreted at the moment. However, the association of high risk pregnancies with C.S., 8 twin (16 babies), 3 triplets (9 babies), 1 quadruplet (4 babies), breech presentation (12 babies), premature (4 babies), 6 infants of diabetic mothers, and 6 of them weighed more than 4.2 kg. This could give some explanation of this uncommonly high rate of C.S. Statistical analysis was based mostly on count of the hips

and not the number of babies. C.S. was not found to a risk factor for ultrasound abnormalities of the screened cases [24,28] .

Among all the above risk factors, the present results pointed to a high incidence of DDH in infants of diabetic mothers (20 hips). All were stable clinically with no click. None of them had any congenital or orthopaedic abnormalities. Four out of 20 hips had abnormal ultrasound findings (2IIa^{-} 2 D hip) i.e. 20%, which is highly significant. Therefore, infants of diabetic mothers could be considered as a new risk factor for DDH as a part of caudal malformation, which is commonly observed in those infants.

It is important enough to emphasize that both clinical and ultrasound examination should follow strict rules and methodology to ensure early detection of any possible hip dysplasia[29,30,31,32] .

CONCLUSION :

Standard ultrasound screening for hip instability is based mainly on Graf's static approach as well as Harck's dynamic method.

Ultrasound screening of the hip has been used as :

i) A primary screening test for all babies [33]

ii) A selective primary method for babies with risk factors, and

iii) It is used as a screening method to decide which babies with physical findings require splintage to reduce over treatment [34].

Ultrasound performed in the neonates before discharge could result in considerable over diagnosis of unstable hips which would normally resolve spontaneously. If it is deferred until two weeks after birth, it would allow for the effect of maternal relaxin hormone to subside and prevent considerable logistical problems with high costs, which cannot currently be justified. There is no clear evidence of benefit [35] if ultrasound is done early to detect DDH. The recommendation in this study is that the best time to do ultrasound for neonatal hip screening is at two weeks of age for all neonates and just before discharge for those babies in the high risk group.

REFERENCES :

1. Graf R. Classification of hip joint dysplasia by means of Sonography. Arch Orthop trauma Surg 1984; 102: 248-55.
2. Moria C, Harcke H T, MacEwen GD. The Infant hip: Real time ultrasound assessment of acetabular development. Radiology 1985; 157: 673-7.
3. Gravey M, Donoghue VB, Gorman WA, O'Brian N, Murphy JFA. Radiographic screening at 4 months of infants at risk for congenital hip dislocation. J Bone-Joint-Syrg (Br) 1992;74:704-707.
4. Castelein R.M.; Sauter AJ, de-Vlieger M, van Linge B. Natural history of ultrasound hip abnormality in clinically normal newborn. J Pediatric - Orthop 1992 July-Aug; 12(4) 423-7.
5. Graf R. Fundamentals of sonographic diagnosis in infants hip dysplasia. J. Pediatr Orth 1989; 4: 735-740.
6. Ortolani M. The classic congenital hip dysplasia in the light of early and very early diagnosis. Clin Orthopedic 1976; 119:6-10.
7. Barlow TG. Early diagnosis and treatment of congenital dislocation of the hip. J. Bone joint Surg [Br] 1962; 44-B: 292-301.
8. Halkawi H, Asir B, Tadros F, Khasawneh Z. Sonographic Image of the newborn hip with positive ortolani sign. Clin Orthop 1992; Jun (279): 138-43.
9. Tonnis D, Storch K, Ulbrich H. Results of newborn screening for CDH with and without sonography and correlation of risk factors. J. Pediatric Orth, 1990; 10:145-152.

10. Leck I. An epidermiological assessment of neonatal Screening for dislocation of the hip. Journal of the Royal College of Physicians of London 1986; Vol 20: No.1 56-62.
11. Joracholmen V. Introduction of the Graf's method in a country hospital experiences and results of ultrasonography in diagnosis of congenital hip joint dysplasia. Tridsskr – Nor – Laegeforen 1995 Aug 10; 115(18): 2249-51.
12. Gomesh R, Menant EAUB. Sonography of the neonatal hip, a dynamic approach. Ann Radiol 1987; 30: 503-510.
13. Harcke HT, Grissom LE. Performing dynmic sonographic of the infant hip. AJR 1990; 155: 837-844.
14. Clarke NM, Harcke HT, McHugh P, Lee MS, Boms PF. Real time ultrasound in the diagnosis of congenital dislocation and dysplasia of the hip. J Bone Joint Surg (Br) 1985; 67(3): 406-412.
15. Tesser et al. Early ultrasound diagnosis of developmental dysplasia of hip. Bull-Hosp Jr dis 1996; 54(4): 222-5.
16. Terjesen T, Rund e'a TO, Tangerud A. Ultrasound screening of hip joint in newborn infants. Tidsskr-Nor-Laege Foren 1993 May 30; 113(14): 170 6-9.
17. Ketil H, Terjesen T, Tegnander A, Bredland, T. Ultrasound screening for hip dysplasia in newborn. Journal of Paed Orthopedic 1994 (14): 667-673.
18. Grill F, Muller D. Results of hip ultrasound sonographic screening in Austria. Orthopade 1997 (Jan; 26(1): 25-32.
19. Martin AJ, Sanz AJ, Yubero-Pascual J, Pedras-Garcia MC. Risk factors in 130 children suspected with hip dysplasia J. An Esp Pediatrics 1991 Dec; 35(6): 409-12.

20. Bialik V, Berant M. Immunity of Ethiopian to developmental dysplasia of the hip, a preliminary sonographic study. J. Pediatrik Orth [B] 1997 Oct; 6(4): 253-9.
21. Szepesi J, Szabo E, Hattyar A. Results of sonographic hip examination of infants in a risk group. Magy-Traumatol-Orthop – Helyneallito-Sebesz 1992; 35(1): 19-23.
22. Hernandez R, Hensinger R. Developmental dysplasia of hip and ultrasound. More is less? Arch Pediatrics – Adolescent Med. Vol 149, Jun 1995; 641-42.
23. Riboni, G, Serantoni S, De-Simoni M, Bascape P. Echography of the hip in the newborn `1507 cases. Radio-Med Torino, 1991 Jan-Feb; 81(1-2):53-7.
24. Clegg J. Routine ultra sound screening for neonatal hip instability. The 1st three years experience in Coventry England. The Coventry & Warwickshire Hospital – England Pediatrika Madrid 1993, 100-103.
25. Walter rs, Donadson JS, Davis CL, Shkolinil A, Binns HJ. Ultrasound screening of high risk infants. A method to increase detection of congenital dysplasia of the hip. Am. J. Dis Children, 1992 Feb; 146(2):230-4.
26. Ulveczki E. U.S. Screening for congenital hip dysplasia. ORV-Hetil 1992 Jun 14;133(24): 1481-3.
27. Psenner K, Ortore P, Fodor G. Echography of the hip of the newborn infants. Radiol-Med Torino 1990 Jun; 79(6): 575-81.
28. Engesaeter LB, Wilson DJ, Nag D, Benson MKD. Ultrasound and congenital dislocation of the hip. The importance of dynamic assessment. J. Bone Joint Surg. [Br] 1990; 72-B: 197-201.
29. Suzuki S. Ultrasonography of CDH via anterior approach. Shiga Medical Center for Children. Pediatrika – Madrid 1993, 56-76.

30. Cyvin KB. Congenital dislocation of the hip. Acta Pediatrica, Scand. 1977; Supp 263-70.

31. Terjesen T, Bredland T, Berg V. Ultrasound for hip assessment in the newborn. J. Bone Joint Surg. [Br] 1989; 71-B: 767-73

32. Carty H. Mini Symposium: The hip in childhood. Current Orthopaedics 1991; 5: 155-62.

33. Abderbbalden, R. Amato M. Early detection of hip dysplasia in the neonatal period Monat sschr – Kinder heiled 1991 Aug; 139 (8) 471-5

34. Ballerini G, Avanzin A, Colombo T. Neonatal screening and follow-up of congenital hip luxation using echography. Review of literature and personal contribution on 14214 newborns. Radiology-Med Torino 1990 Dec; 80 (6): 814-7.

35. Sobky M, Jabber S. Does routine sonography of the neonate hip induce over treatment? The New Egyptian Journal of Medicine, Vol:11 No.:5 Nov. 1994: 74-81.

Table 1

Synopsis of Sonographic hip-types according to Graf

Type	Bony roof	Bony rim	Cartilaginous roof	Total
I Mature hip joint 1A + 1B	Good	Angular/blunt	Narrow covering	>60
IIa <3 months Physiologically immature				
11a+ appropriate for age	Sufficient	Round	Wide, covering	50 - 59
IIa^{-} maturity deficit	Deficient	Round	Wide, covering	50 - 59
11b (>3 months)	Deficient	Round	Wide, covering	50 - 59
Delay of ossification IIc (any age)	Severely	Round or flat	Wide, but still covering	43 - 49<77
Critical	Deficient			
D (any age)	Severely	Round or flat	Displaced	43 - 49 >77
Decentering hip	Deficient			
III Eccentric (decentered hip)				
IIIa	Poor	Flat	Displaced cranially Without structural Alterations=hypoechoic	<43
IIIb	Poor	Flat	Displaced cranially with structural Alterations=Echogenic	<43
IV eccentric (decentered hip)	Poor	Flat	Displaced inferomedially	<43

Table 2

Physiological and Pathological Hip

Type of hip	Right	Left	Total right & left hip
Physiological			
Ia	22	40	62
Ib	457	413	870
Iia	178	169	347
II a+	80	91	171
Total Physiological Hip	**737**	**713**	**1450**
Pathological			
IIa^{-}	49	65	114
IIc	0	5	5
IIIa	0	2	2
D	23	24	47
Total Pathological Hip	**72**	**96**	**168**

Table 3

Prenatal data related to newborns with unstable hips by Ultrasound and clinical examination and to those with stable hips

Group of newborn	Total No. of Hips	Number of unstable Hips	U/S abnormal hips					%
			Total No.	IIa⁻	IIc	D	IIIa	
Breech	42	2	9	6	0	3	0	21.4 %
Premature	12	0	0	0	0	0	0	0 %
Cesarean	442	3	30	21	1	8	0	6.7 %
Orthopaedic anomalies	8	0	4	2	0	2	0	50 %
Down	4	0	0	0	0	0	0	0 %
Twins	32	3	3	3	0	0	0	9 %
Triplets	18	0	0	0	0	0	0	0 %
Quadruplets	8	0	0	0	0	0	0	0 %
Family history	2	0	2	1	0	1	0	100 %
IUGR	8	0	0	0	0	0	0	0 %
IODM	20	0	4	2	0	2	0	20 %

IODM : Infant of Diabetic mother.

IUGR : Intra-uterine growth retardation

Table 4

Ultrasound findings according to the four different groups based on clinical and ultrasound (U.S.) examination

	Total No. of newborn	%	Ia	Ib	IIa	IIa^{+}	IIa^{-}	IIb	IIc	D	IIIa
Normal Ortolani Ultra Sound Normal	1420	87.7%	62	8540	3410	163	0	0	0	0	0
Positive Ortolani U.S. Pathological	30	1.85%	0	0	0	2	12	0	2	14	0
Positive Ortolani U.S. Normal	28	1.73%	0	16	6	6	0	0	0	0	0
Normal Ortolani U.S. Pathological	140	8.65%	0	0	0	0	102	0	3	33	2

Table 5

The numbers of unstable hips in each Graf's sonographic type

	RIGHT		LEFT	
	Total	Unstable	Total	Unstable
Ia	22	0	40	0
Ib	457	5	413	10
IIa	178	3	169	3
IIa^{+}	80	3	91	3
IIa^{-}	49	6	65	9
IIb	0	0	0	0
IIc	0	0	5	2
IIIa	0	0	2	0
D	23	8	24	6
TOTAL	809	25	809	33

Figure 1

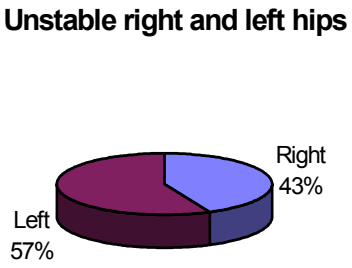

Figure 2

The groups of hips according to ultrasound pathology and clinical instability

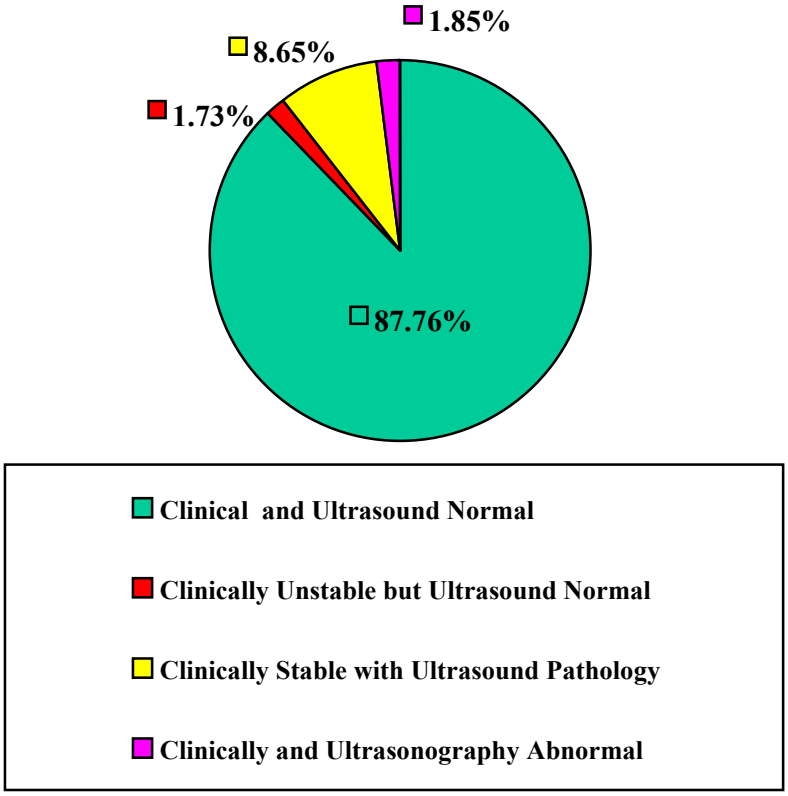

Figure 3

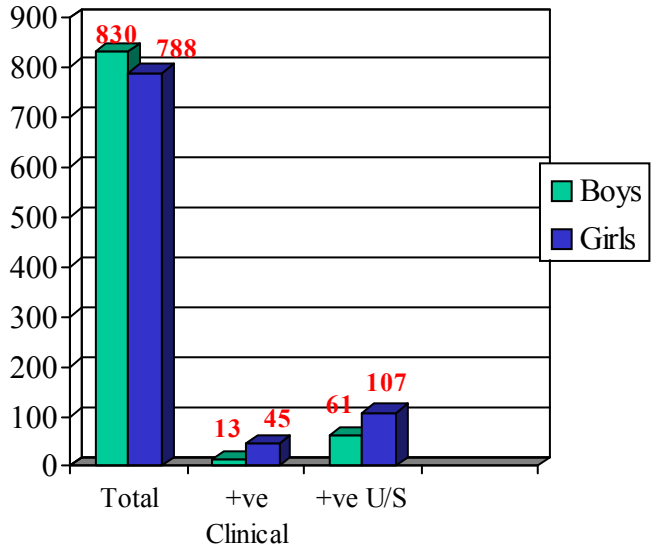

Figure 4

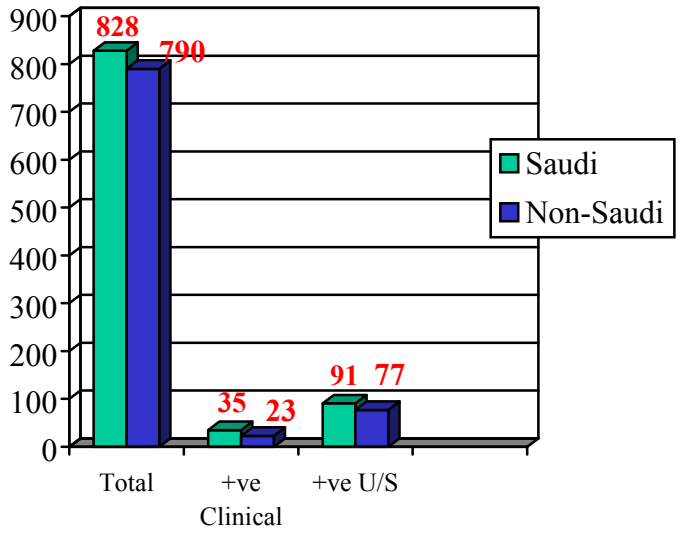

Figure 5

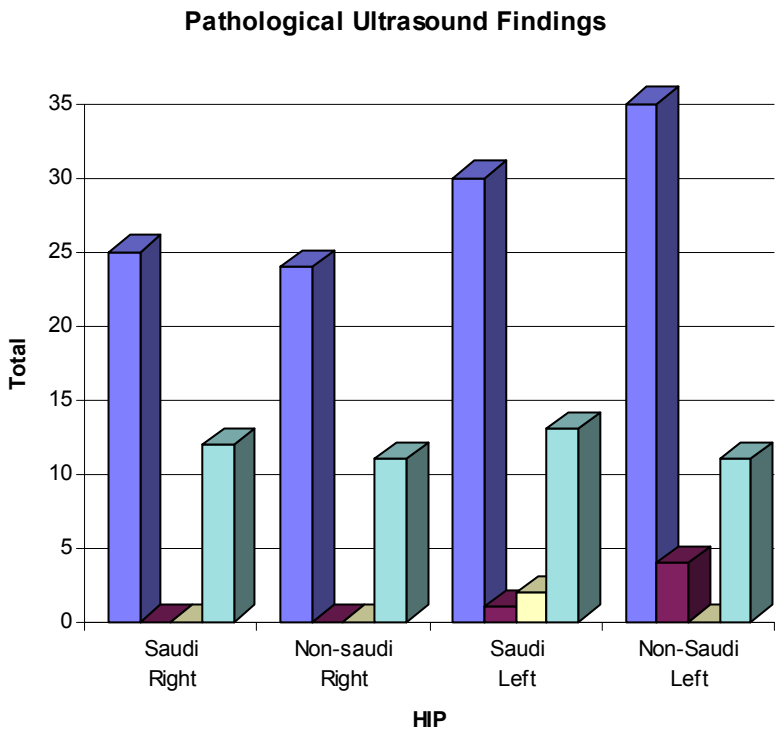
Pathological Ultrasound Findings
35
30
25
20
15
10
5
0
Total
Saudi Right
Non-saudi Right
Saudi Left
Non-Saudi Left
HIP