

## **Non-Surgical Epicanthoplasty and Rhinoplasty: Epicanthorhinoplasty**

**Amal A. Bukhari**, MD, FRCS

*Department of Ophthalmology, Faculty of Medicine  
King Abdulaziz University, Jeddah, Saudi Arabia  
aabukhari@kau.edu.sa*

*Abstract.* To describe a new non-surgical method to correct both medial epicanthal fold and flat nasal dorsum simultaneously using subdermal filler injections. Six patients were injected with 0.8 to 1 ml of injectable Hyaluronic Acid or hydroxyapatite fillers. The mean follow up was 9 months (6-12 months). All patients demonstrated an immediate satisfactory aesthetic improvement that was observed till the filler material was biodegraded. Two patients developed prolonged cutaneous hyperemia at the injection site and another one developed a fistula that resolved spontaneously after 10 days. Sub-dermal injectable fillers may provide a transient, faster, relatively safe, with a non-scar forming method to correct epicanthal folds and depressed nasal bridge simultaneously without the risks of traditional surgical procedures.

*Keywords:* Epicanthal fold, Epicanthoplasty, Rhinoplasty, Asian face.

### **Introduction**

The Asian face has unique characteristics including small eyes, which is accentuated by the presence of single eyelid, medial epicanthal fold and a broad flat nasal dorsum. Besides the aesthetic influence, epicanthal folds can affect the judgment about the direction of gaze as it makes it very differently from gaze from eyes that don't have these folds. A difference that is sensitive to cultural experience of the observers<sup>[1]</sup>.

---

Correspondence & reprint request to: Dr. Amal A. Bukhari  
P.O. Box 80215, Jeddah 21589, Saudi Arabia  
Accepted for publication: 11 February 2010. Received: 21 November 2009.

Due to the shift of the beauty standards to the westernized features, Asians seek plastic surgeries to approach those standards. A wider looking eye can be greatly achieved by eliminating the medial epicanthal fold and by nasal bridge augmentation.

Because the traditional surgical methods carry the risk of anesthesia, bleeding, infections, fibrosis and scarring, besides the need for a time off to undergo multiple surgeries and for rehabilitation. This is a quick, safe and painless office procedure that eliminates epicanthal folds and augment the nose simultaneously with an immediate aesthetic results.

### **Materials and Methods**

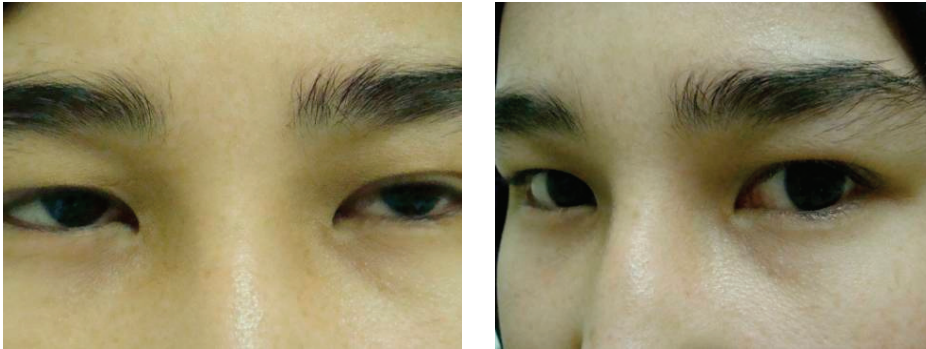
Six Asian females with a median age of 34 (20-43) years were recruited. All patients had flat nasal dorsum and a medial epicanthal fold of variable degrees. After obtaining an informed consent, Topical Lidocaine Cream (emla® Cream 5%) was repeatedly applied over the nasal dorsum over 15-20 minutes to provide sufficient anesthesia. Two patients received TEOSYAL® Ultra Deep, Hyaluronic Acid (Laboratories Teoxane S.A., Geneve, Switzerland), two other patients received Perlane (Q-Med AB, Uppsala, Sweden) and two received Radiesse® Hydroxyapatite (BioForm Medical, San Mateo, CA USA).

With a bevel directed up a 30-gauge needle for hyaluronic acid and 27-gauge needle for hydroxyapatite was introduced; 2 mm deep in the dermal space and pushed up parallel to the skin surface using the linear threading technique. The filler was then injected while the needle is withdrawn. Minimal side-to-side pressure was applied to stop any bleeding points. The technique was then repeated for further adjustments, if needed. A mild overcorrection was aimed for patients who received hyaluronic acid to compensate for the edema that was expected to occur during the procedure. 0.8 - 1.00 cc of filler material was needed per patient, depending on the degree of the epicanthal fold. Patients left the clinic immediately after the procedure and were evaluated again after 2 weeks. Touch ups were given at that time whenever needed. Further follow up visits were at 1 month, 3 months, 6 months and at 12 months. Patient satisfaction was recorded on a scale of 0-5, where zero means total dissatisfaction and 5 corresponds to full satisfaction. All patients left the clinic satisfied with the aesthetic results (Fig. 1-5).

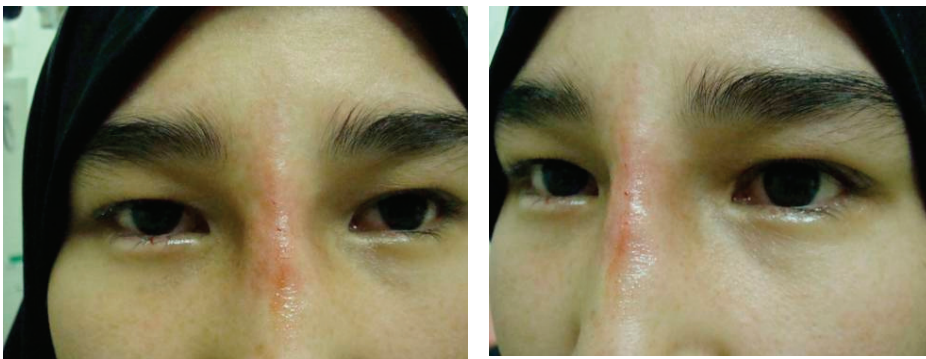
## **Results**

The two patients who received TEOSYAL® Ultra Deep Hyaluronic Acid injections developed cutaneous hyperemia over the nasal dorsum that lasted till the material was biodegraded six months later. It was not associated with any signs of inflammation or vascular complications. One of the two patients, who received Radiesse® injection, developed a fistula that discharged the filler material upon mild pressure. It resolved spontaneously after 10 days without any sequel.

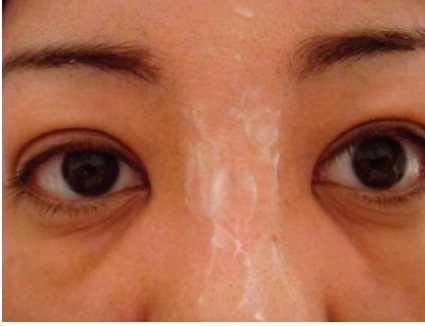Hyaluronic acid was noticed to be biodegraded 6 months after the procedure, and hydroxyapatite lasted for 12 months post injection.



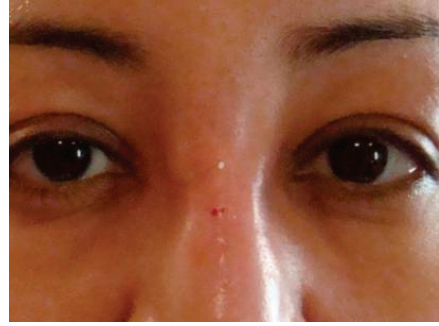**Fig. 1. Patient 1: Before treatment.**



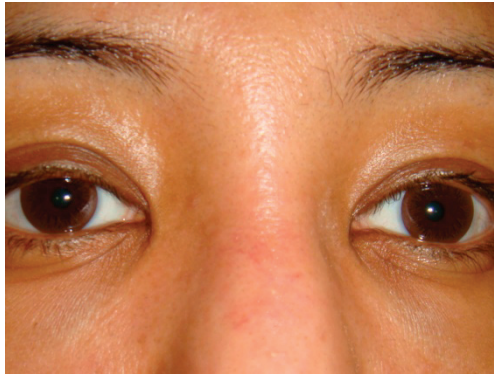**Fig. 2. Patient 1: After treatment showing the hyperemia that lasted till the filler was biodegraded.**



**Fig. 3. Patient 2: Before treatment.**



**Fig. 4. Patient 2: After treatment showing the fistula.**



**Fig. 5. Patient 2: one year after treatment.**

All patients were highly satisfied by the results. Those who developed complications were less satisfied initially, but that improved gradually with time.

### **Discussion**

The use of dermal fillers for non-surgical rhinoplasty has been described by Cassuto<sup>[1]</sup> and others<sup>[2,3]</sup>. However this is the first report on its use for simultaneous correction of medial epicanthal folds and flat nasal dorsum.

This is a faster, one step procedure that does not carry the risk of chronic nasal bleeding, nasal obstruction, infections, visible scars, implant extrusion, rejection, malpositions, and visible scars<sup>[4-7]</sup> like the traditional epicanthoplasties and rhinoplasties<sup>[8-12]</sup>.

The two minor complications occurred among our patients were persistent hyperemia and fistula. Both of which resolved spontaneously without any sequel. It's believe that the hyperemia was related to the brand of filler as it only occurred with patients that received TEOSYAL® Ultra Deep Hyaluronic Acid. In addition, it resolved as the filler material that was completely biodegraded. This complication was never reported when TEOSYAL® Ultra Deep Hyaluronic Acid was used in other parts of the face. A larger scale study is needed to be able to recommend avoidance of any brand for such procedure.

With regard to the fistula, it's believed that the cause was due to the short needle track obtained when the filler was injected into that very first patient in the series. Although it resolved spontaneously without any sequel, it strongly stresses on the point of obtaining a needle track not less than half inch before start injecting to avoid this complication, like persistent fistula, implant infection and extrusion.

This pilot study suggests that this procedure can be a good alternative to the traditional methods to enhance the beauty of Asian eyes, as it is simple, fast, safe, and cheap which can give immediate results. The choice of the material determines how long the results will last. Although most people seek long-lasting or even permanent improvements in order to limit the need for recurrent treatments, but as the nose area is less forgiving than the other facial areas, it's recommended the use of a short-lasting material at the first time to ensure that the result meets the patients' expectations. Also, it's believed that it would always be better not to use a permanent material in order to be able to modify it according to the changes that will happen with age in order to achieve a more natural appearance.

#### References

- [1] **Cassuto D.** The use of Dermicol-P35 dermal filler for nonsurgical rhinoplasty. *Aesthetic Surg J* 2009; **29**(3): S22-24.
- [2] **West RW, Salmon TO, Sawyer JK.** Influence of epicanthal fold on the perceived direction of gaze. *Optom Vis Sci* 2008; **85**(11): 1064-1073.
- [3] **Yagi Y, Kato K, Murakami D, Misaki K, Ota M.** Utilization of aquamid as a filler for rhinoplasty in orientals. *Plast Reconstr Surg* 2009; **123**(1): 26e-28e.
- [4] **Raghavan U, Jones NS, Romo T 3rd.** Immediate autogenous cartilage grafts in rhinoplasty after alloplastic implant rejection. *Arch Facial Plast Surg* 2004; **6**(3): 192-196.

- [5] **Romo T 3rd, Rizk SS, Suh GD.** Mucous cyst formation after rhinoplasty. *Arch Facial Plastic Surg* 1999; **1**(3): 208-211.
- [6] **Cakmak O, Buyuklu F.** Crushed cartilage grafts for concealing irregularities in rhinoplasty. *Arch Facial Plast Surg* 2007; **9**(5): 352-357.
- [7] **Porter JP, Tardey ME Jr, Cheng J.** The contoured auricular projection graft for nasal tip projection. *Arch Facial Plast Surg* 1999; **1**(4): 312-315.
- [8] **Yen MT, Jordan DR, Anderson RL.** No-scar Asian epicanthoplasty: a subcutaneous approach. *Ophthal Plast Reconstr Surg* 2002; **18**(1): 40-44.
- [9] **Fuente del Campo A.** A simple procedure for aesthetic correction of the medial epicanthal fold. *Aesthetic Plast Surg* 1997; **21**(6): 381-384.
- [10] **Lin SD.** Epicanthal fold correction with VM-Plasty. *Int J Cosmet Surg Aesthetic Dermatol* 2000; **2**(3): 177-180.
- [11] **Fujiwara T, Maeda M, Kuwae K, Nishino K.** Modified split V-W plasty for entropion with an epicanthal fold in Asian eyelids. *Plast Reconstr Surg* 2006; **118**(3): 635-642.
- [12] **Adamson PA, Galli SK.** Rhinoplasty approaches: current state of art. *Arch Facial Plast Surg* 2005; **7**(1): 32-37.

## إصلاح ثنية موق العين الداخلية والأنف المنخفض بدون جراحة

آمال عبد الكريم بخاري

قسم العيون ، كلية الطب ، جامعة الملك عبد العزيز

جدة - المملكة العربية السعودية

المستخلص. وصف لطريقة جديدة لإصلاح ثنية موق العين الداخلية والأنف المنخفض في نفس الوقت، وبدون تدخل جراحي، تمت دراسة عدد من الحالات المتتابعة بعد حقنها بمواد حشو مختلفة، وتم حقن ستة من المريضات بكميات تتراوح ما بين ٠,٨ - ١ مل من مواد الحشو، وتمت معابنتهم في فترة زمنية تتراوح ما بين الستة أشهر والسنة، وكان جميع المرضى راضين عن النتيجة من بعد الحقن مباشرة من الناحية التجميلية، إلا أن مريضتين أصيبتا باحتقان دموي على الجلد فوق منطقة الحقن، والتي استمرت إلى أن تحللت مادة الحشو، بينما أصيبت إحدى المريضات بناسور، والذي زال بعد عشرة أيام تلقائياً. ونستخلص من ذلك أنه يمكن لحقن الحشو أن يكون ذا فائدة في إصلاح ثنية موق العين الداخلية والأنف المنخفض في نفس الوقت بدون تدخل جراحي، وبدون تعريض المريض لمخاطر ومضاعفات العمليات الجراحية والتي ستؤدي لنفس النتيجة.