

EUROPEAN JOURNAL OF CARDIO-THORACIC SURGERY

Dreadful giant pulmonary arteriovenous fistula

Khaled E. Al-Ebrahim

Eur J Cardiothorac Surg 2011;40:1031-

DOI: 10.1016/j.ejcts.2011.01.047

This information is current as of December 3, 2011

The online version of this article, along with updated information and services, is located on the World Wide Web at:

<http://ejcts.ctsnetjournals.org/cgi/content/full/40/4/1031>

The European Journal of Cardio-thoracic Surgery is the official Journal of the European Association for Cardio-thoracic Surgery and the European Society of Thoracic Surgeons. Copyright © 2011 by European Association for Cardio-Thoracic Surgery. Published by Elsevier. All rights reserved. Print ISSN: 1010-7940.

Images in cardio-thoracic surgery

Dreadful giant pulmonary arteriovenous fistula

Khaled E. Al-Ebrahim *

Department of Cardiac Surgery, King Abdul Aziz University, Jeddah, Saudi Arabia

Received 1 November 2010; received in revised form 7 January 2011; accepted 18 January 2011; Available online 16 March 2011

Keywords: Pulmonary; Arteriovenous; Fistula

A 72-year-old male on haemodialysis and poor physical and mental health presented with haemoptysis. Chest X-ray (Fig. 1) and computed tomography (CT) scan (Fig. 2) showed large right-upper-lobe mass. He suffered sudden cardiac

arrest. Repeat X-ray (Fig. 1) showed opacification of the right haemothorax. Initial chest drainage was minimal followed by massive bleeding.

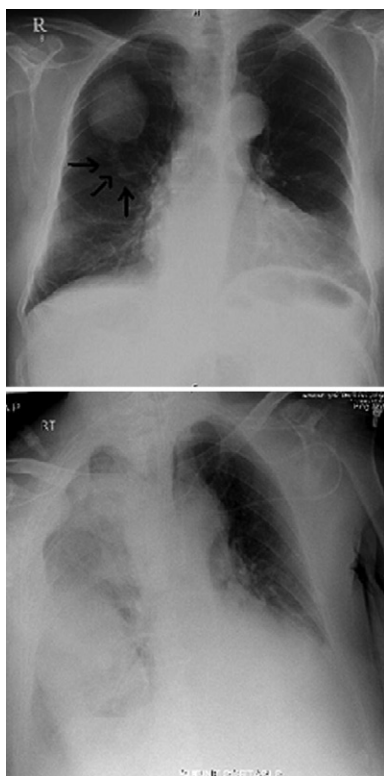


Fig. 1. Chest X-ray before and after the cardiac arrest. Arrows on top X-ray showing one of the large feeding arteries.

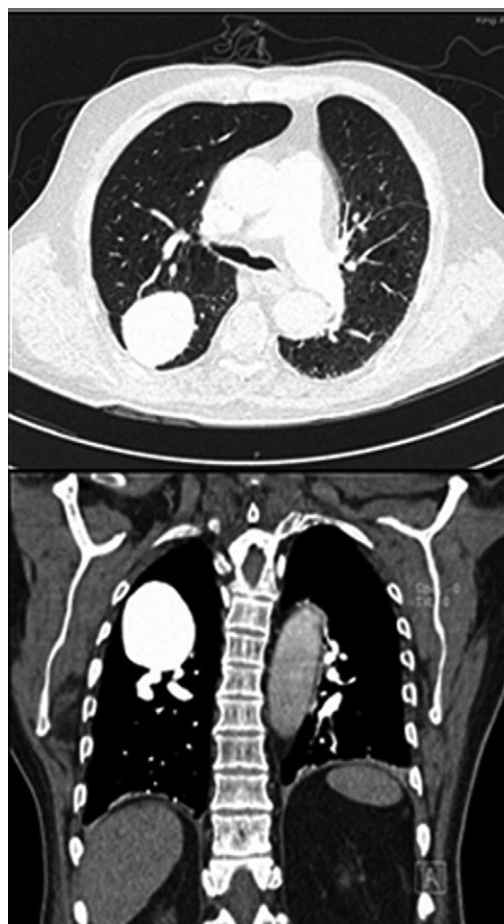


Fig. 2. Computerized tomography scan axial and sagittal sections showing the huge sized (8 cm) pulmonary arteriovenous fistula (PAVF) and at least two large feeding arteries. These PAVF are usually small and rarely attain such size. Coil embolotherapy and surgery are the main lines of management.

* Corresponding author. Address: Department of Cardiac Surgery, King Abdul Aziz University Hospital, P O Box 80215, Jeddah 21589, Saudi Arabia. Tel.: +966 26295224; fax: +966 26408347. E-mail address: dr.k-e@hotmail.com.

Dreadful giant pulmonary arteriovenous fistula

Khaled E. Al-Ebrahim

Eur J Cardiothorac Surg 2011;40:1031-

DOI: 10.1016/j.ejcts.2011.01.047

This information is current as of December 3, 2011

Updated Information & Services	including high-resolution figures, can be found at: http://ejcts.ctsnetjournals.org/cgi/content/full/40/4/1031
Subspecialty Collections	This article, along with others on similar topics, appears in the following collection(s): Lung - other http://ejcts.ctsnetjournals.org/cgi/collection/lung_other
Permissions & Licensing	Information about reproducing this article in parts (figures, tables) or in its entirety can be found online at: http://ejcts.ctsnetjournals.org/misc/Permissions.shtml
Reprints	Information about ordering reprints can be found online: http://ejcts.ctsnetjournals.org/misc/reprints.shtml

EUROPEAN JOURNAL OF
CARDIO-THORACIC
SURGERY